

# Planas Direct Tracks for Early Crossbite Correction

GERMAN OMAR RAMIREZ-YAÑEZ, DDS, MDSC

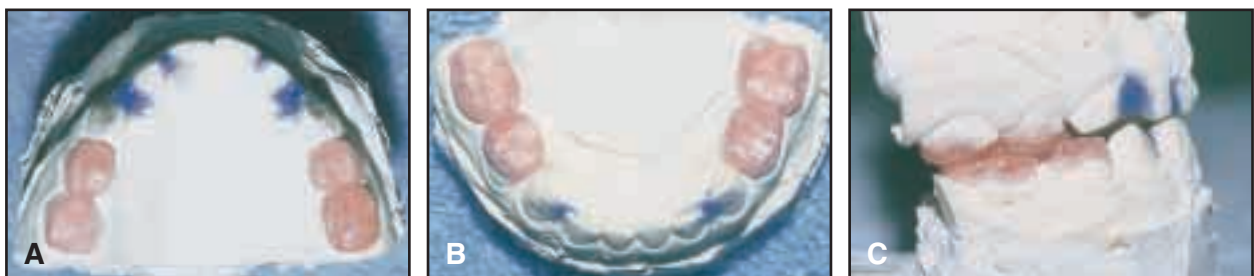
**T**his article describes the use of composite inclined planes called Planas Direct Tracks (PDTs) to correct more complex cases of crossbite in the deciduous dentition.<sup>1-10</sup>

## Planas Direct Tracks


Prof. Pedro Planas of Spain initially developed PDTs,<sup>1</sup> and Simoes<sup>11</sup> adapted them for early prevention of anterior or posterior crossbite. PDTs should be used in the deciduous dentition only, as they cover the occlusal surfaces of the molars, resulting in a flat posterior occlusion until the molars are exfoliated.

PDTs can be built in the laboratory using an indirect technique. A wax bite registration should be taken in an edge-to-edge incisor relationship. The casts are then mounted on an articulator; a separate articulator is recommended to facilitate working with each cast individually. If selective grinding is required, it should be performed on the casts before the tracks are constructed and then reproduced in the mouth.

The tracks are built out of self-curing acrylic, first on the lower cast (Fig. 1). For a posterior crossbite, the inclined plane is contoured from lingual to buccal on the lower deciduous molars of the crossbite side only (Fig. 2). For an



**Fig. 1** A. Upper cast with tracks built up on deciduous molars. Interproximal spaces between anterior teeth were filled with wax to avoid creating retentive areas during acetate tray construction. B. Lower cast with tracks built up on deciduous molars. C. Articulation of upper and lower casts. Selective grinding has been performed on upper canine to increase mesial facet of cusp, permitting better lateral excursion when mandible is repositioned.



**Fig. 2** Inclination of tracks on upper and lower deciduous molars.



Dr. Ramirez-Yañez is a doctoral student in dentistry, Department of Oral Biology and Pathology, School of Dentistry, University of Queensland, St. Lucia, Queensland 4072, Australia, and in the private practice of orthodontics in Cucuta, Colombia; e-mail: germanramirez@hotmail.com.

anterior crossbite, the inclined plane is contoured from distal to mesial on the lower deciduous molars on both sides. The tracks should cover the entire occlusal surfaces of each molar, extending to about the middle third of the buccal and lingual surfaces to provide optimum retention. It is extremely important to build the track individually on each molar, following the overall direction of tapering required to correct the crossbite.

Once a smooth contour is obtained, the lower track is covered with transparent tape to isolate it during construction of the upper track. Both upper and lower casts are articulated, and the upper track is built by copying the inclination

from the lower deciduous molars. The vertical dimension is increased until the occlusion is supported on the tracks and no dental contact occurs, allowing the mandible to be repositioned in centric occlusion. Exaggerated increases of the vertical dimension should be avoided. In some cases, the deciduous canines may be included in the tracks to provide mandibular displacement or to avoid contacts that would block mandibular repositioning.

An acetate transfer tray is constructed for each arch (Fig. 3). The deciduous molars are etched with 37% orthophosphoric acid for 15 seconds. The acetate tray is then loaded with

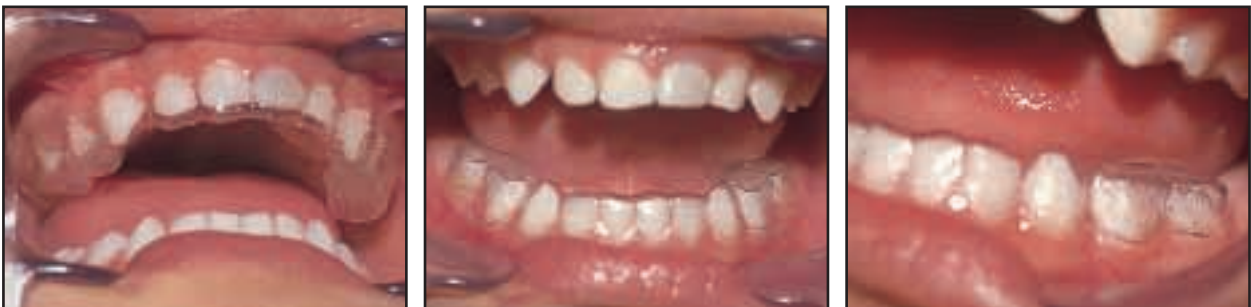

Fig. 3 Acetate trays before being filled with light-cured composite.

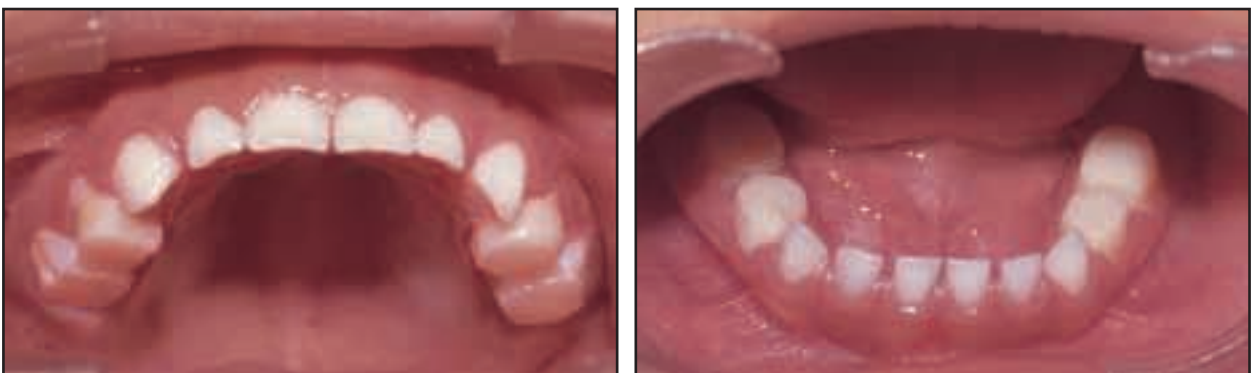
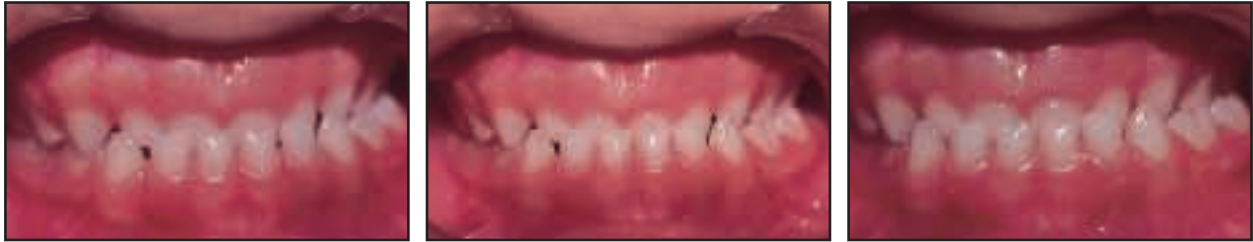
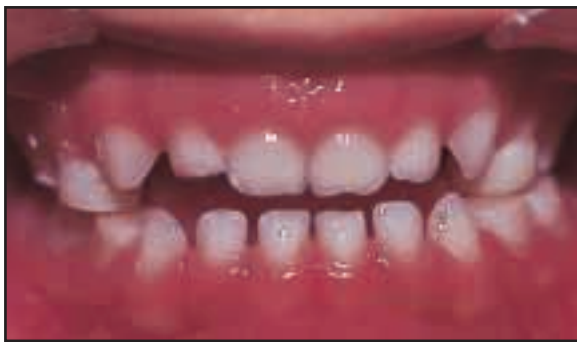Fig. 4 PDTs bonded to deciduous molars.



**Fig. 5** 4½-year-old female patient with crossbite from right lateral incisor to left second deciduous molar before treatment.



**Fig. 6** PDTs bonded directly to deciduous molars.

light-cured composite in the areas of the tracks. No composite should be loaded in the incisor region, as these teeth are the reference points for setting the transfer trays. The composite resin is cured for at least 40 seconds on each molar surface. We have found it more comfortable to build the lower PDTs first, but the tracks should be placed in both arches at the same appointment.

After removal of the transfer trays, the occlusion is adjusted with a round No. 140 bur to permit an exact intercoupling of the tracks (Fig. 4). A very fine No. 200 diamond point may be used to remove any particular contacts within the tracks in the interproximal areas.

PDTs can be built directly in the mouth, but this requires a highly skilled and experienced operator, as well as a high degree of patient cooperation. The procedure is the same as described above, but the tracks are built directly with composite resin on the deciduous teeth, and the acetate trays are not used.

### Case Report

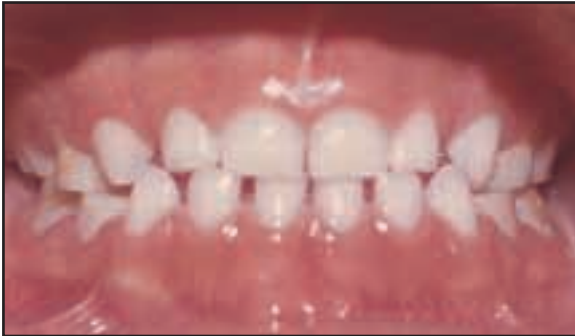A girl age 4 years, 6 months, in the deciduous dentition presented with a crossbite extending from the right lateral incisor to the left second deciduous molar (Fig. 5). The patient had a distal-step molar occlusion between the second deciduous molars on the crossbite side and a mesial-step occlusion on the other side, with a Class I canine relationship and generalized spacing.

The treatment goal was to correct the crossbite at this early stage to prevent maxillofacial discrepancies during later growth and development. After selective grinding,<sup>1,11</sup> PDTs with a combined inclination for posterior and anterior crossbites were designed.

The PDTs were built in one appointment using a direct technique, as patient cooperation was excellent (Fig. 6). The occlusion was adjusted with articulating paper to fit the upper and lower tracks together. In addition, a tapered diamond bur was used to ensure that the interproximal areas around each molar were separated. When the PDTs were finished, the patient displayed an anterior open bite.

The patient was advised to eat normally and to report back if any fractures were seen in the tracks or any discomfort occurred. At her next scheduled appointment, one month later, a close edge-to-edge relationship could be observed. The crossbite was completely corrected in another month (Fig. 7). The patient was then seen every three months to monitor subsequent growth and development.

A stable occlusal relationship was maintained after eruption of the first permanent molar



**Fig. 7** Crossbite correction after two months of wearing PDTs. Note minor diastema between deciduous incisors and better alignment of anterior segments.

and permanent incisors (Fig. 8). The PDTs remained on the deciduous molars until they exfoliated. The patient reported no problems with eating during this entire period.

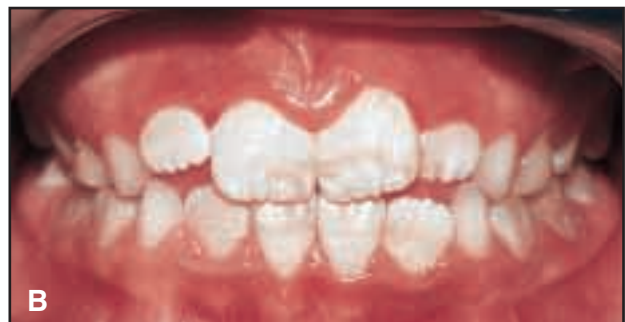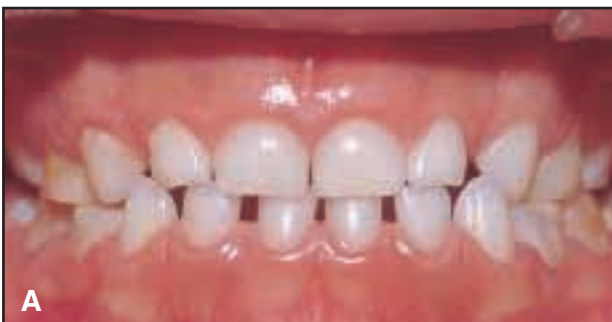### Discussion

When the jaws approach and contact is nearly reached between the opposing teeth, muscle activity is adjusted to locate both condyles concentrically in the glenoid fossae. Crossbite does not permit proper settlement of the condyle on the opposite side, forcing its posterior temporalis muscle to become more active.<sup>12</sup> As a result of the muscular imbalance, the mandible becomes significantly longer on the non-crossbite

side than on the crossbite side.<sup>1,4,11,13-16</sup> Furthermore, the condyle is positioned more superiorly and posteriorly on the crossbite side, with a narrower and shorter condyle head.<sup>4,16</sup> In other words, the condyle on the non-crossbite side is located forward and downward in the glenoid fossa, while the condyle on the crossbite side is positioned backward and upward.

The TMJs adapt to displacements of the mandible by condylar growth and surface remodeling of the fossae.<sup>1,14-17</sup> Although a causative relationship has not been proven between crossbite and TMD, studies have found a greater incidence of some signs and symptoms in children with crossbite.<sup>18</sup> Therefore, early crossbite treatment is important not only to achieve normal growth and development, but also to help prevent TMD.

Planas Direct Tracks work by repositioning the mandible, thus preventing the establishment of morphological and positional asymmetries in young children and allowing a more symmetrical craniofacial development.<sup>1,16-30</sup> PDTs can be used to correct either posterior or anterior crossbite in the deciduous dentition, regardless of the severity of the malocclusion.<sup>31</sup> Nevertheless, a higher rate of success can be expected in young patients in whom a skeletal discrepancy has not yet been established. Even if a second phase of treatment becomes necessary, it will probably be simpler and shorter if permanent asymmetries have been prevented during prepubertal growth.



**Fig. 8** A. Stability of correction after eruption of first permanent molar. B. Stability after eruption of permanent incisors, with tracks still covering occlusal surfaces of deciduous molars.

## REFERENCES

1. Planas, P.: *Rehabilitación Neuro-Oclusal (RNO)*, 2nd ed., Masson-Salvat Odontología, Barcelona, Spain, 1994.
2. Zhu, J.F.; Crevoisier, R.; King, D.L.; Henry, R.; and Mills, C.M.: Posterior crossbites in children, *Compend. Cont. Ed. Dent.* 17:1051-1054, 1996.
3. Sugiyama, H.; Lee, K.; Imoto, S.; Sasaki, A.; Kawata, K.; Yamaguchi, K.; and Tanne, K.: Influences of vertical occlusal discrepancies on condylar responses and craniofacial growth in growing rats, *Angle Orthod.* 69:356-364, 1999.
4. Akahane, Y.; Deguchi, T.; and Hunt, N.P.: Morphology of the temporomandibular joint in skeletal Class III symmetrical and asymmetrical cases: A study by cephalometric laminography, *J. Orthod.* 28:119-127, 2001.
5. Martín, C.; Alarcón, J.A.; and Palma, J.C.: Kinesiographic study of the mandible in young patients with unilateral posterior crossbite, *Am. J. Orthod.* 118:541-548, 2000.
6. Harrison, J.E. and Ashby, D.: Orthodontic treatment for posterior crossbites, *Cochrane Database Syst. Rev.* No. 2, 2002.
7. Huggare, J.: Postural disorders and dentofacial morphology, *Acta Odontol. Scand.* 56:383-386, 1998.
8. Kenworthy, C.R. and Sheats, R.D.: A bonded functional ramp to aid in asymmetric expansion of unilateral posterior crossbites, *Am. J. Orthod.* 119:320-323, 2001.
9. Thilander, B.; Wahlund, S.; and Lennartsson, B.: The effect of early interceptive treatment in children with posterior crossbite, *Eur. J. Orthod.* 6:25-34, 1984.
10. Sari, S.; Gokalp, H.; and Aras, S.: Correction of anterior dental crossbite with composite as inclined plane, *Int. J. Paed. Dent.* 11:201-208, 2001.
11. Simoes, W.A.: Selective grinding and Planas direct tracks as a source of prevention, *J. Pedod.* 5:298-314, 1981.
12. Alarcón, J.A.; Martín, C.; and Palma, J.C.: Effect of unilateral posterior crossbite on the electromyographic activity of human masticatory muscles, *Am. J. Orthod.* 118:328-334, 2000.
13. Simoes, W.A.: *Ortopedia funcional de los maxilares vista a traves de la rehabilitación neuro-oclusal*, 2nd ed., Isaro, Barcelona, Spain, 1989.
14. Simoes, W.A.: Insights into maxillary and mandibular growth for a better practice, *J. Clin. Pediat. Dent.* 21:1-8, 1996.
15. Lam, P.H.; Sadowsky, C.; and Omerza, F.: Mandibular asymmetry and condylar position in children with unilateral posterior crossbite, *Am. J. Orthod.* 115:569-575, 1999.
16. Pinto, A.S.; Buschang, P.H.; Throckmorton, G.S.; and Chen, P.: Morphological and positional asymmetries of young children with functional unilateral posterior crossbite, *Am. J. Orthod.* 120:513-520, 2001.
17. Nerder, P.H.; Bakke, M.; Solow, B.: The functional shift of the mandible in unilateral posterior crossbite and the adaptation of the temporomandibular joints: A pilot study, *Eur. J. Orthod.* 21:155-166, 1999.
18. Sonnesen, L.; Bakke, M.; and Solow, B.: Malocclusion traits and symptoms and signs of temporomandibular disorders in children with severe malocclusion, *Eur. J. Orthod.* 20:543-559, 1998.
19. Ferrario, V.F.; Sforza, C.; and Serrao, G.: The influence of crossbite on the coordinated electromyographic activity of human masticatory muscles during mastication, *J. Oral Rehab.* 26:575-581, 1999.
20. Throckmorton, G.S.; Buschang, P.H.; Hayasaki, H.; and Pinto, A.S.: Changes in the masticatory cycle following treatment of posterior unilateral crossbite in children, *Am. J. Orthod.* 120:521-529, 2001.
21. Sonnesen, L.; Bakke, M.; and Solow, B.: Bite force in pre-orthodontic children with unilateral crossbite, *Eur. J. Orthod.* 23:741-749, 2001.
22. Sohn, B.W.; Miyawaki, S.; Noguchi, H.; and Takada, K.: Changes in jaw movement and jaw closing muscle activity after orthodontic correction of incisor crossbite, *Am. J. Orthod.* 112:403-409, 1997.
23. Tsarapatsani, P.; Tullberg, M.; Lindner, A.; and Huggare, J.: Long-term follow-up of early treatment of unilateral forced posterior cross-bite: Orofacial status, *Acta Odontol. Scand.* 57:97-104, 1999.
24. McNamara, J.A.: Maxillary transverse deficiency, *Am. J. Orthod.* 117:567-570, 2000.
25. Tullberg, M.; Tsarapatsani, P.; Huggare, J.; and Kopp, S.: Long-term follow-up of early treatment of unilateral forced posterior cross-bite with regard to temporomandibular disorders and associated symptoms, *Acta Odontol. Scand.* 59:280-284, 2001.
26. Carlson, D.S.: Biological rationale for early treatment of dentofacial deformities, *Am. J. Orthod.* 121:554-558, 2002.
27. McNamara, J.A. Jr.: Early intervention in the transverse dimension: Is it worth the effort? *Am. J. Orthod.* 121:572-574, 2002.
28. Klumper, G.T. and Spalding, P.M.: Realities of craniofacial growth modification, *Atlas Oral Maxillofac. Surg. Clin. N. Am.* 9:23-51, 2001.
29. De Boer, M. and Steenks, M.H.: Functional unilateral posterior crossbite: Orthodontic and functional aspects, *J. Oral Rehab.* 24:614-623, 1997.
30. Mauck, C. and Trankmann, J.: Influence of orthodontic treatment in the primary dentition upon development of the dentition and craniofacial growth, *J. Orofac. Orthop.* 59:229-236, 1998.
31. Gribel, M.N.: Planas Direct Tracks in the early treatment of unilateral crossbite with mandibular postural deviation: Why worry so soon? *World J. Orthod.* 3:239-249, 2002.